

NEET SS

LAST MINUTE REVISION



S.No	TOPIC	Page No
1.	TUMORS classifications	1
2.	TRAUMA Classifications	37
3.	Triads	43
4.	Triangles	46
5.	HLAs & Half Lives	50
6.	Timings of Paediatric surgery	51
7.	Investigations	52
8.	Important Signs	55
9.	Investigations Findings	56
10.	The First...	58
11.	Genes and chromosomes +	59
12.	M/C sites , Ectopic sites	71
13.	Cancers and nodes	
14.	Classifications +	
15.	Scores	
16.	Ideal Timing of procedures & Tumor Margin clearance	
17.	Criteria	
18.	Ulcers in GIT & Endoscopy findings	
19.	Indications of surgeries	
20.	Prophylactic surgeries	
21.	Named Operations	
22.	Trials	
23.	Syndromes	
24.	Microbes	
25.	-mabs+	
26.	Most commons	
27.	Tables +	

American Joint Committee on Cancer Staging for Soft Tissue Sarcomas

Primary Tumor (T)	
Primary tumor cannot be assessed	TX
No evidence of primary tumor	T0
Tumor 5 cm or less in greatest dimension	T1
Tumor more than 5 cm and less than or equal to 10 cm in greatest dimension	T2
Tumor more than 10 cm and less than or equal to 15 cm in greatest dimension	T3
Tumor more than 15 cm in greatest dimension	T4

Regional Lymph Nodes (N)	
Regional lymph nodes cannot be assessed	NX
No regional lymph node metastasis	N0
Regional lymph node metastasis	N1

Distant Metastasis (M)	
No distant metastasis	M0
Distant metastasis	M1

ANATOMIC STAGE AND PROGNOSTIC GROUPS FOR SOFT TISSUE SARCOMAS.

GROUP	T	N	M	GRADE
Stage IA	T1	N0	M0	G1, GX
Stage IB	T2-T4	N0	M0	G1, GX
Stage II	T1	N0	M0	G2, G3
Stage IIIA	T2	N0	M0	G2, G3
Stage IIIB	T3,T4	N0	M0	G2, G3
Stage IV	Any T	N1*	M0	Any G
Stage IV	Any T	Any N	M1	Any G

For retroperitoneal sarcoma, N1 disease is designated as stage IIIB, not stage IV.

World Health Organization Classification of Salivary Gland Neoplasms (2017)

Malignant Epithelial Tumours
Acinic cell carcinoma
Mucoepidermoid carcinoma
Adenoid cystic carcinoma
Polymorphous low-grade adenocarcinoma
Epithelial-myoepithelial carcinoma
Clear cell carcinoma, Not Otherwise Specified
Basal cell adenocarcinoma
Sebaceous carcinoma
Sebaceous lymphadenocarcinoma
Cystadenocarcinoma
Low-grade cribriform cystadenocarcinoma
Mucinous adenocarcinoma
Oncocytic carcinoma
Salivary duct carcinoma
Adenocarcinoma, Not Otherwise Specified
Myoepithelial carcinoma
Carcinoma ex pleomorphic adenoma
Carcinosarcoma
Metastasising pleomorphic adenoma
Squamous cell carcinoma
Small cell carcinoma
Large cell carcinoma
Lymphoepithelial carcinoma
Sialoblastoma

Benign Epithelial Tumours
Pleomorphic adenoma
Myoepithelioma
Basal cell adenoma
Warthin's tumour
Oncocytoma
Canalicular adenoma
Sebaceous adenoma
Lymphadenoma - Sebaceous - Non-sebaceous
Ductal papillomas - Inverted ductal papilloma - Intraductal papilloma - Sialadenoma papilliferum
Cystadenoma

Soft-tissue Tumours
Haemangioma

Haematolymphoid Tumours
Hodgkin's lymphoma
Diffuse large B-cell lymphoma
Extranodal marginal zone B-cell lymphoma

Histological Grades of salivary gland cancers

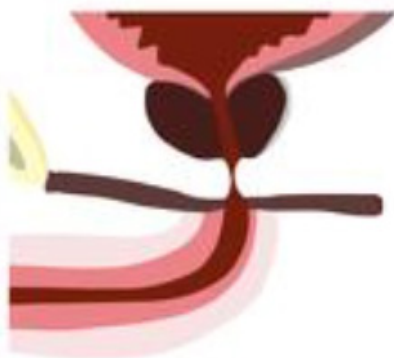High Grade
High-grade mucoepidermoid carcinoma
Salivary duct carcinoma
Adenoid cystic carcinoma
Carcinoma ex pleomorphic adenoma
Squamous cell carcinoma
Anaplastic or undifferentiated carcinoma
Malignant mixed carcinoma

Low to Intermediate Grade
Low-grade mucoepidermoid carcinoma
Acinic cell carcinoma
Polymorphous low-grade adenocarcinoma
Epithelial-myoepithelial carcinoma

URINARY BLADDER TRAUMA

DESCRIPTION		GRADE
Contusion /intra mural hematoma Partial thickness laceration		I
Extra peritoneal UB wall laceration < 2cm	Intra peritoneal	II
>2cm	< 2cm	III
	>/=2 cm	IV
Laceration extending into Bladder Neck or ureteral orifice (trigone)		V

Goldman classification of urethral injuries



Type I

stretching of the posterior urethra due to disruption of puboprostatic ligaments



Type II

posterior urethral injury above urogenital diaphragm



Type III

injury to the membranous urethra, extending into the proximal bulbous urethra



Type IV

bladder base injury involving bladder neck extending into the proximal urethra



Type IVa

bladder base injury but not involving bladder neck



Type V

anterior urethral injury

Injury Type	Injury Description	Urethrographic Appearance	Treatment
1	Contusion	Normal	None
2	Stretch injury	Elongation of the urethra without extravasation	Conservative management with suprapubic or urethral catheterization
3	Partial disruption	Extravasation of contrast agent from the urethra with opacification of the bladder	Conservative management with suprapubic or urethral catheterization
4	Complete disruption	Extravasation of contrast agent from the urethra without opacification of the bladder and with urethral separation < 2 cm	Endoscopic realignment or delayed graft urethroplasty
5	Complete disruption	Complete transection with urethral separation > 2 cm or extension of injury to the prostate or vagina	Endoscopic realignment or delayed graft urethroplasty

Gustilo and Anderson Open Fracture Classification

Type	Description
I	A low-energy open fracture with a wound less than 1 cm long and clean.
II	An open fracture with a laceration more than 1 cm long without extensive soft-tissue damage, flaps, or avulsion.
III	Characterised by high-energy injury irrespective of wound size. Extensive soft-tissue damage involving muscles, skin, and neurovascular structures, with a high degree of contamination. Fractures are multifragmentary and unstable.

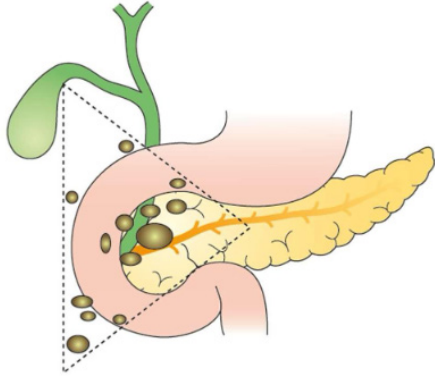
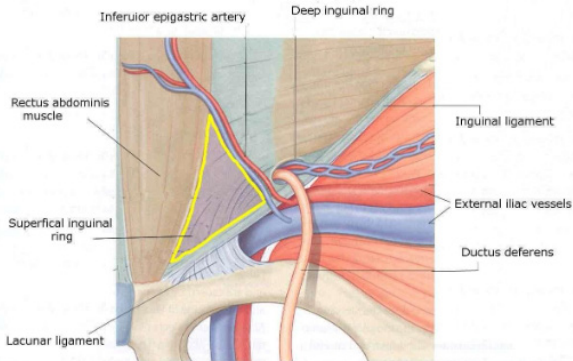
Priorities in the mangled extremity

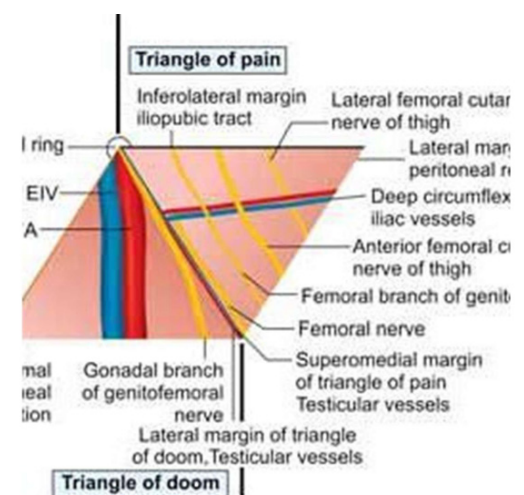
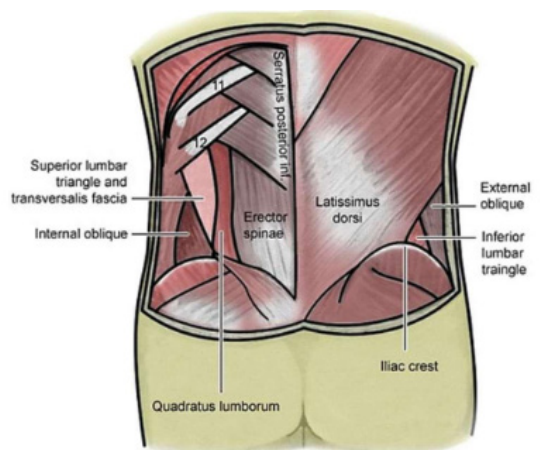
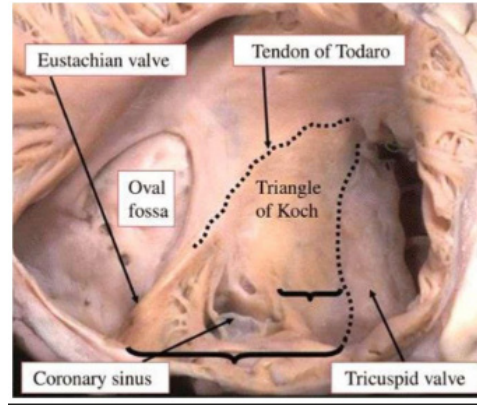
- Revascularization
- Temporary bony fixation
- Soft tissue coverage
- Definitive bony reconstruction
- Tendon and nerve reconstruction

Subtype	Description
III A	Adequate soft-tissue cover of a fractured bone after stabilization.
III B	Inadequate soft-tissue cover of a fractured bone after stabilization (i.e., flap coverage required).
III C	Open fracture associated with an arterial injury requiring repair.

S.no	Name of triad	Components
1	Achalasia Cardia	Dysphagia Regurgitation Weight loss
2	Allgrove syndrome	Alacrimia + Achalasia + Adrenal gland insufficiency
3	Anderson triad / Mackler's triad	Boerhaave's syndrome
4	Beck triad (seen in Cardiac tamponade)	Hypotension, distended neck veins, and muffled heart sounds
5	Borchardt triad	Sudden onset of constant and severe upper abdominal pain + Recurrent retching with production of little vomitus + Inability to pass an NG tube
6	Budd Chiari Syndrome	Abdominal pain, Ascites and Hepatomegaly.
7	Carney's triad	<ul style="list-style-type: none"> • Pulmonary chondroma • Gastric leiomyosarcoma -GIST • Functional adrenal paraganglioma – non familial
8	Charcot's triad	Intermittent Pain, Fever, Jaundice
9	Currarino triad	<ul style="list-style-type: none"> • Sacral malformation • Anorectal malformation (often stenosis) • Presacral mass consisting of a dermoid Cyst/teratoma and/or anterior meningocele.
10	Cushing's triad	<ul style="list-style-type: none"> • Hypertension • Bradycardia • Irregular respiration
11	Dieulafoy's Triad (seen in appendicitis)	<ul style="list-style-type: none"> • Hyperesthesia of the skin in RIF • Mc Burney's point tenderness • Muscle guarding
12	Galezia Triad	<ul style="list-style-type: none"> • Dupuytren's contracture • RPF • Peyronie's disease of penis
13	Gilroy Bevan Triad of adhesive pain	<ul style="list-style-type: none"> • Pain may get aggravated or relieved by change of posture • Pain in the region of old abdominal scar • Tenderness elicited by pressure over the scar
14	Goldenhar's complex	<ul style="list-style-type: none"> • Branchial cleft anomalies • Biliary atresia • Congenital cardiac anomalies
15	Haimovici triad of revascularization of an acutely ischemic limb	<ul style="list-style-type: none"> • Muscle infarction • Myoglobinuria • Acute renal failure

S.no	Name of triad	Components
16	Hakim's triad /Adam's triad (seen in Normal pressure hydrocephalus)	<ul style="list-style-type: none"> Gait disturbance, incontinence and cognitive decline. (gait ataxia, incontinence, and dementia)
17	Heyde's syndrome	Aortic Stenosis + Angiodysplasia
18	Loyes-Dietz Syndrome (Triad)	<ul style="list-style-type: none"> Arterial tortuosity, Aneurysms Hypertelorism (widely spaced eyes) Bifid uvula or Cleft palate
19	Mackler's triad - Boerhaave's syndrome	<ul style="list-style-type: none"> Vomiting Chest pain Subcutaneous emphysema
20	Most brain tumours will present with one or more features related to the following triad	<p>Raised ICP Seizures Focal deficit</p>
21	Murphy's triad	Acute appendicitis Pain f/b Vomiting f/b Fever
22	Mycetoma	<ul style="list-style-type: none"> Painless subcutaneous mass Multiple sinuses Seropurulent discharge
23	Ohashi triad (seen in IPMN Pancreas)	Bulging ampulla of Vater (Fish mouth ampulla) Mucin secretion Dilated main pancreatic duct.
24	Pancoast's Triad (seen in Pancoast's tumor)	<ul style="list-style-type: none"> Excruciating pain in arm Horner's syndrome Erosion of ribs
25	Prune belly triad (Prune belly syndrome)	<ul style="list-style-type: none"> Cryptorchidism Abdominal wall defects Genitourinary defects
26	Rigler's triad	<ul style="list-style-type: none"> Gall stone ileus(Ectopic gallstone) Pneumobilia Small Bowel Obstruction
27	Ruptured abdominal aortic aneurysm	<ul style="list-style-type: none"> Severe abdominal and/or back pain Hypotension Pulsatile abdominal mass.
28	Saint's triad HCG	<ul style="list-style-type: none"> Hiatus hernia Colon Diverticulosis Gallstones
29	Sandblom's triad /Quincke's Triad – Triad of Haemobilia	<ul style="list-style-type: none"> Upper abdominal pain, UGI hemorrhage Jaundice

S.no	Name of triangle	Description
7	Gastrinoma Triangle aka: Passaro's triangle	<ul style="list-style-type: none"> • Junction of the neck and body of the pancreas medially • Junction of the second and third parts of the duodenum inferiorly • Junction of the cystic and common bile ducts superiorly 
8	Hesselbach's triangle aka : Inguinal Triangle	<ul style="list-style-type: none"> • Inferior epigastric vessels laterally, • Lateral edge of rectus abdominis muscle medially • Inguinal ligament below (the iliopubic tract) 
9	Triangle of doom Vessels : • EIA • EIV • Deep Circumflex Iliac veins	

S.no	Name of triangle	Description
10	<p>Triangle of Pain</p> <p>Nerves (medial to lateral):</p> <ul style="list-style-type: none"> • Femoral Nerve • Femoral branch of GFN • Anterior cutaneous N of thigh • Lateral cutaneous N of thigh 	
11	<p>Inferior Lumbar Triangle of Petit</p> <p>Anterior: External oblique</p> <p>Posterior: Latissimus dorsi</p> <p>Inferior: Iliac crest</p>	
12	<p>Superior Lumbar triangle of Grynfeltt</p>	
13	<p>TRIANGLE OF SAFETY</p>	<ul style="list-style-type: none"> • Posteriorly by latissimus dorsi, • Anteriorly by the lateral border of pectoralis major and • Inferiorly by a line perpendicular to the nipple going to the back, just anterior to the mid-axillary line
14	<p>TRIANGLE OF KOCH</p>	<ul style="list-style-type: none"> • Anterior: Annulus of septal leaflet of Tricuspid valve • Posterior: Tendon of Todaro (Fibrous extension from Eustachian valve) • Inferior: Orifice of coronary sinus 

HLA	Condition
HLA I	A B C
HLA II	DP DQ DR
HLA allograft rejection antigens are on chromosome	6p
HLA DR>B> A	HLA matching -Beneficial effect on allograft survival
HLA A B DR	Mismatching sequence A mismatch of 0-0-0, i.e. no mismatches at A, B or DR, respectively
HLA B 08	Celiac disease
B 12	EHBA
B 27	IBD arthritis Reiter's disease
DRB1*03	Idiopathic retroperitoneal fibrosis

IMPORTANT HALF LIVES

Substance	Half life
PTH	3-5 min
Free PSA	2-3 hrs
LDH	24 hrs
HCG	24-36 hrs
PSA	2-3 days
AFP	5-7 days
Free T3	1 day
Free T4	7 days

Age	Diseases						
Neonatal period	1st procedure in EXSTROPHY BLADDER REPAIR: Bilateral iliac osteotomies with bladder exstrophy and abdominal wall closure						
6- 8 weeks	Kasai Procedure for EHBA						
3-6 months	Cleft lip repair						
6 months	<ul style="list-style-type: none"> Epispadias repair and phallic reconstruction at 6 months to 1 year of age (2nd procedure in EXSTROPHY BLADDER REPAIR) Cleft lip (@3-6 months) Cleft Palate (Before 1 year / before speech development) 						
As soon as Diagnosed	<ul style="list-style-type: none"> Midgut Volvulus (Emergency) 						
6-12 months	Ankyloglossia or Tongue tie						
6-12 months	UDT Rx; Premature babies: Corrected to Gestational age						
15 – 18 months	Hypospadias repair						
Before 1 year / Before speech development	(6 months – 1 year) Cleft palate repair						
2 years	Congenital hydrocele						
3 years > 5 years	Umbilical hernia						
5–7 years	Bladder neck reconstruction and bilateral ureteric reimplantation (to treat VUR) (3rd procedure in EXSTROPHY BLADDER REPAIR)						
ABG(Alveolar Bone Grafting)	<ul style="list-style-type: none"> When permanent dentition begins and after orthodontic preparation <table border="1"> <thead> <tr> <th>Primary ABG</th> <th>Early 2ndary</th> <th>Late 2ndary</th> </tr> </thead> <tbody> <tr> <td>At the same time as primary cleft lip surgery</td> <td>@ 5-7 years</td> <td>@ 8-11 years</td> </tr> </tbody> </table>	Primary ABG	Early 2ndary	Late 2ndary	At the same time as primary cleft lip surgery	@ 5-7 years	@ 8-11 years
Primary ABG	Early 2ndary	Late 2ndary					
At the same time as primary cleft lip surgery	@ 5-7 years	@ 8-11 years					
Congenital Inguinal Hernia	<ul style="list-style-type: none"> Term child : As soon a diagnosed Preterm: Counted to corrected gestational age Complicated hernia : Immediate 						

CONDITION	Investigation
If an Anastomatic leak is suspected following Roux-en -Y Gastric bypass metabolic surgery IOC is	CECT abdomen – Gastrograffin
IOC for diagnosis of CSF rhinorrhea	Beta 2 transferrin
IOC for Confirmation of CSF rhinorrhea	CT Cisternogram
MRI tech that uses anisotropic diffusion to estimate the axonal organization of the brain	Diffusion tensor imaging
IOC for trigeminal neuralgia	MRI angiography
Investigation of choice for GIST	CT abdomen ; Biopsy is not mandatory MRI is better for rectal And duodenal GIST
Gold standard for diagnosis of insulinoma	72 hours Monitored Fast
IOC for PSC	MRCP
Suspicion of lymphedema	IOC = Lymphoscintigraphy Or Isotope lymphography
Midgut volvulus	Gold standard = Laparotomy or D.Lap
Diagnostic study of choice for Complete non rotation of the mid gut	Upper GI contrast series
Hirschsprung	Diagnostic imaging of choice = Contrast enema ; Gold standard = Full thickness rectal biopsy
H. Pylori infection	-Gold std. = Histology(Mucosal biopsy) -Most cost effective = Stool antigen test (90% accurate in detecting eradication of infection after Rx) -100% Specific = Rapid urease Test -Evaluation of serum antibodies is the test of choice for initial diagnosis when endoscopy is not required but has the drawback of remaining positive after treatment and eradication of infection.
Hydrocephalus in children (Gold standard for the diagnosis)	CT brain
Intussusception	Gastrograffin enema
Gold std for Ischemic colitis	Colonoscopy
Brain absces	
Cerebral aneurysm	Gold standard = DSA
Brain tumor	Initial investigation = CT brain IOC = gadolinium contrast MRI
IOC for diagnosis of colonic diverticula	Barium enema
IOC for Diverticulitis	CECT abdomen (Modified Hinchey Classific.)
IOC for diagnosis of Bleeding colonic diverticula	Colonoscopy; both the diagnostic and Therapeutic
Confirmatory test of Ogilvie syndrome	CT abdomen

CONDITION	Investigation
Gold standard for diagnosis of Ischemic colitis	Flexible endoscopy (Single stripe sign)
Multi cystic dysplastic kidney MCDK	Antenatal ultrasound Isotope renal scan
IOC for CUPJO	Isotope Diuretic Renography(MAG-3)
IOC for diagnosis of RCC	CECT abdomen (CT urogram)
Small Bowel NET (Best method for staging)	Octreotide scan
Splenic abscess (IOC)	CECT abdomen
Urachal Anomaly (IOC)	Children: USG / MCUG Adolescents: MRI
The best first-line test for bone lesions and fractures	Radiographs
MRI is good for diagnosing bone marrow disease, occult fractures and tendon and soft-tissue disorders	
Best method for detecting muscle hernias	USG
Best method for rotator cuff tear	USG
The only method for locating non-metallic foreign bodies	USG
Best method of distinguishing solid from cystic lesions	USG
Best investigation in patients suspected of active GI bleeding	CT Mesenteric angiogram
Current gold standard for diagnosis of genito urinary tuberculosis	Urine AFB culture
Gold standard investigation for bladder carcinoma	Cystourethroscopy and biopsy
Investigation of choice for abscess following epidural anesthesia is?	MRI
Best imaging modality to detect renal Parenchymal lesions	DMSA
Glomerular filtration rate	DTPA
Renal tubular function	MAG 3
Confirmatory test for posterior urethral valves	VCUG
IOC for diagnosis of upper tract uroepithelial cancers	CT urogram
Confirmatory test for the diagnosis of celiac disease	Duodenal biopsy (even though Anti Endomysial Antibodies are highly sensitive and specific)
Most specific diagnostic tests for testicular torsion	Radio isotope scanning
Most accurate method of staging local disease in Prostate cancer	mpMRI

Important Signs in Surgery

Names	Condition
Balance sign	Unilateral shifting dullness in splenic trauma
Battle Sign	Middle Cranial fossa Fracture- Pigmentation at mastoid process
Blue dot sign	Torsion of Appendages of testis(Hydatid Of Morgagni)
Blumberg sign	Acute appendicitis- Rebound Tenderness
Chvostek sign	Hypocalcemia- Facial twitching
Cullen sign	Periumbilical pigmentation in Hemorrhagic pancreatitis
Dunphy sign	
Durkan test	
Fox Sign	Acute Pancreatitis – Inguinal region Ecchymosis
Froment sign	Should be able to grasp the paper with the thenar adductor alone. Positive test is flexion of the thumb IP joint, which uses the median innervated FPL.
Grey Turner Sign	Loin pigmentation in hemorrhagic pancreatitis
Groove sign (Sign of Groove)	LGV; Matted nodes above and below the inguinal ligament
Hamman’s sign	Boerhaave syndrome
Kehr’s sign / Danforth sign	Referred pain to left shoulder in splenic trauma
Klein’s Sign	Mesenteric Adenitis- Shifting tenderness
Le Dance Sign	Intussusception- Examination shows Empty right iliac fossa
Lyre sign	Carotid Body tumor
Nicoladoni’s sign/ Branham’s Sign	AV Fistula- Clinical sign
Obturator sign	
Ransohoff’s Sign	Yellow discoloration around umbilicus due to CBD rupture
Rovsing sign	
Spurling sign	Pain with downward pressure on the vertex while tilting the head toward the symptomatic side--- cervical disc herniation
Ten Horn Sign	
Tinel sign	Reproduction of numbness and tingling and/or pain in the affected nerve distribution
Troisier’s sign	Left supra clavicular node enlargement
Trosseau sign	Hypocalcemia- Carpal spasm
Wartenberg sign	Ulnar Drift of little finger away from ring finger indicates weakness of the ulnar innervated intrinsics and pull of the radially innervated EDC/EDQ

Investigation Findings and names

Imaging finding	Disease
Accordion sign / Concertina sign on CECT abdomen	Clostridium difficile colitis (High attenuation oral contrast in colon lumen alternating with low attenuation inflamed mucosa)
Ace of spades appearance/ Bird beak appearance on Barium Enema	Sigmoid volvulus
Apple core appearance On Barium swallow On Barium Enema	Ca Esophagus Carcinoma Colon
Bird Beak appearance in Barium swallow	Achalasia cardia
Beads on string appearance on MRCP	PSC
Bear's paw sign on CECT Abdomen	Xanthogranulomatous pyelonephritis
Central dot sign	Caroli's disease
Central scarring and a hypervascular lesion on CECT or MRI	FNH Liver
Chain of Lakes	Chronic Pancreatitis
Claw sign / Pincer sign / Coiled Spring sign on BARIUM ENEMA	Intussusception
Claw sign on CT	Wilms tumor
Cobra head sign on IVU	Ureterocele
Coffee bean sign / Bent inner tube sign/Omega colon	Sigmoid volvulus (More of ANTI CLOCKWISE)
Comb Sign	CECT finding in mesentery with prominent venules in Crohn's Disease
Comma shaped caecum	Caecal volvulus (more of Clockwise)
Cork Screw esophagus	Diffuse esophageal spasm
Double duct sign on MRCP Epsilon / Reverse 3 sign on Barium Meal	Ca Head of Pancreas
Dot-in-circle sign	Mycetoma foot (MRI foot indicating grains)
Drooping Lilly sign	Neuroblastoma and Duplex Ureter- IVP finding
Doughnut sign / Target sign / Bulls eyes appearance/ Pseudo kidney appearance on USG	Intussusception
Fat ring sign on CT	Normal adipose tissue surrounding Mesenteric vessels in Sclerosing mesenteritis

THE FIRST....

Heart lung machine / Open Heart Surgery	Gibbon
Successful CABG	M.E.DeBakey
Beating heart CABG	V Subramanian
Cardiac surgery done by	Robery gross PDA ligation
Heart transplant	BARNARD
Lung transplant	Fritz Derom Bailey 28th : James Hardy
Heart lung transplant	Bruce Reitz and Shumway
Kidney transplantation	Joseph Murray
Liver transplant	STARLZ
LDLT : Children Successful LDLT in children	Silvano Raia Russell Strong
LDLT in adults	Tanaka
Split LIVER TRANSPLANT	Pichlmayr
Human whole organ pancreas transplant	Richard Lillehei and William Kelly
Human pancreatic islet transplantation	David Sutherland and John Najarin

3rd space loss	Alfred Blalock
Father of Thyroid surgery	Theoder Kocher
Father of Bariatric surgery	Edward Mason

Chromosomes, Genes & Proteins

Disease	Chromosome Number
Von Hippel Lindau (VHL)	3 p
T3 receptor genes alpha and beta are present on... ..chromosomes	3,17
FAP Gardner syndrome	5 q
HLA	6p
Pendred Syndrome	7q
PRSS 1 (Protease Serine- Regulates TRYPSINOGEN production)	7
PapiLLary RCC is a result of aberrations in..... ..chromosomes	7 ,17 and Y
Naevoid basal cell carcinoma (Gorlin's) syndrome Ferguson- Smith syndrome Xeroderma pigmentosum	9 q
PTEN Cowden's disease	10
RET oncogene (MEN 2A Syndrome) / Hirschsprung	10 q
WT 1	11p13
WT 2 Beckwith- Wiedemann syndrome	11p15
MEN 1 (Wermer syndrome) -- Menin protein	11 q 13
Specific genetic marker for all types of adult germ cell tumors	Isochrome of short arm of chromosome 12
Retinoblastoma	13
BRCA 2	13 q

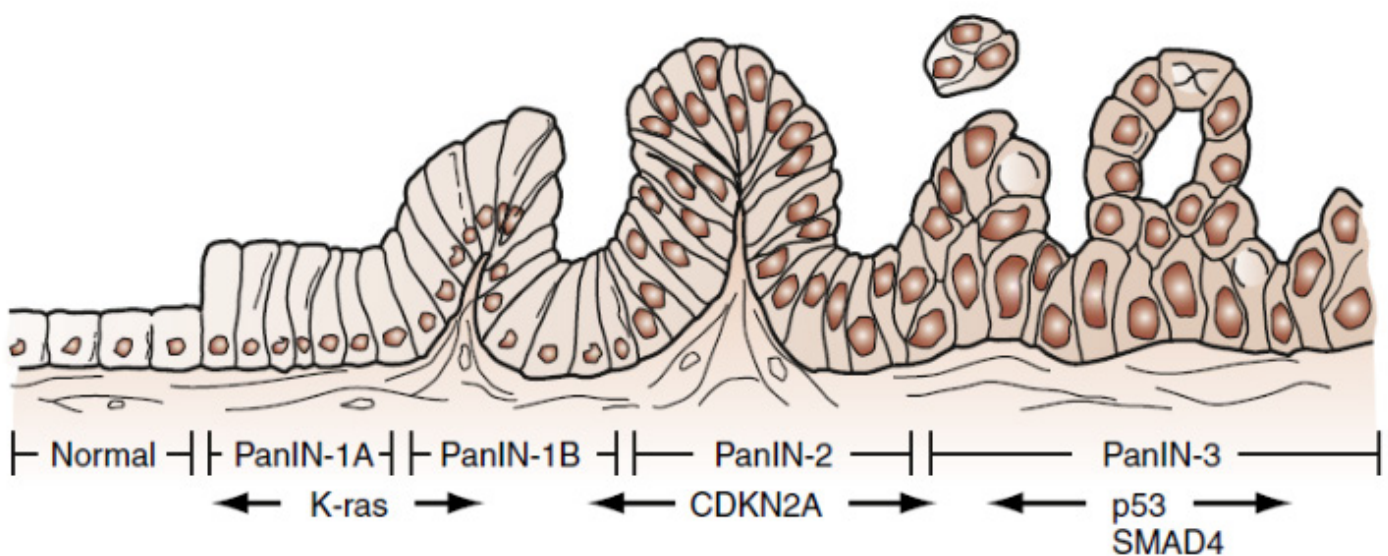
INHERITANCE PATTERNS AUTOSOMAL RECESSIVE:

- Xeroderma pigmentosum
- Bloom syndrome
- Ataxia telangiectasia
- Familial mediterranean fever
- Werner syndrome
- MUTYH polyposis
- CFTR

Arx, Aristaless related homeobox; Pax-4, paired box gene 4; PDX1, insulin promoter factor 1; PTF1, pancreas-specific transcription factor 1.

Hereditary risk factors associated with development of pancreatic cancer

GENE	ASSOCIATED SYNDROME	CLINICAL SIGNIFICANCE
PRSS1	Familial pancreatitis	Mutation results in chronic pancreatitis and 40% lifetime risk of PDAC.
STK11	Peutz-Jeghers syndrome	Mutation results in >100-fold increase in risk of PDAC.
CDKN2A	Familial atypical mole and multiple melanoma syndrome	Mutation leads to increased risk of melanoma and >40-fold increase in risk of PDAC.
CFTR	Cystic fibrosis	Thick secretions result in chronic pancreatitis and 30-fold increase in risk of PDAC.
BRCA2	Hereditary breast and ovarian cancer	Mutation results in elevated risk of breast and ovarian cancer and 10-fold increase in risk of PDAC.
MLH1	Lynch syndrome	Mismatch repair gene mutation leads to increased risk of colon cancer and 8-fold increase in risk of PDAC.
APC	Familial adenomatous polyposis	Mutation results in polyposis coli and colon cancer with 4-fold increase in risk of PDAC.



Molecular genetic progression from pancreatic intraepithelial neoplasia (PanIN) to invasive ductal adenocarcinoma. (Adapted from Wilentz RE, Iacobuzio-Donahoe CA, Argani P, et al. Loss of expression of

CONDITION	M/c site
FAP Associated Desmoid tumors	Bowel mesentery
Gastrinoma	D1 (Passaro's triangle)
Liposarcoma	Proximal thigh
Leiomyosarcoma	Uterus
Angiofibroma	Trunk > H&N (In HEAD: M/C SITE = Scalp) M/C site of metastasis = Lungs
Neuroblastoma	Abdomen>Chest>neck>Pelvis
Colorectal Cancer	Rectum > Sigmoid
Bowel affected in Crohn's	Terminal ileum
Fibrovascular polyp of esophagus	Upper 1/e of esophagus
Leiomyosarcoma esophagus	Lower middle 1/3 or upper aspect of lower 1/3 of esophagus
Granular cell tumor esophagus / Squamous papilloma	Lower 1/3 of esophagus
Breast cancer	Upper outer quadrant > Central quadrant

CONDITION	M/c site
Cerebral aneurysm	ACA & Anterior Communicating Artery
EDH	Pterion
Hypertensive Rupture causing bleed	Putamen (Basal ganglia)
Extranodal lymphoma	Stomach
M/C site of cancer in Crohn's disease	Ileum
M/C Site of GIST	Stomach > Jejunum & Ileum > Duodenum
M/C Site of Carcinoid tumor	Overall : Bronchus (GIT : Appendix)
M/C Site of Schwannoma	Vagus nerve (Bailey : Page 810)

Cancers and Nodes

Cancer	Related nodes
Sentinel node of Penile Cancer	Cabana
Sentinel node of Breast cancer	Guiliano node
Sentinel node of Prostate, Bladder cancer	Obturator node
Sentinel node of Anal Squamous cancer	Superficial Inguinal Node
Sentinel node of Thyroid Cancer	Delphian Nodes (Pre laryngeal nodes)
Sentinel node of Cancer Gallbladder	Lund node / Mascagni node
Left Supraclavicular Nodal mets	Virchow's node
Left Axillary Node mets in Cancer stomach	Irish Node
Sentinel Node of Testis	Para aortic Node

– Selective neck dissection in oral cavity cancer is done if risk of nodal metastasis is < 20%.

– Elective neck dissection is indicated in oral cancer with DOI > 3 mm.

- Breast- 10 nodes
- Esophagus - 26 nodes
- Stomach- 16 nodes
- Small Bowel- 10 nodes
- Colon – 12 nodes

Minimum Number of Nodes removed:

Non ampullary Duodenal cancers	5
Gallbladder	6
Peri hilar	7
Small Bowel adenocarcinoma	8
Jejuno ileal	9
Breast	10
Colon cancer	12
Breast	15
Stomach	16

Breast Malignancy –Axillary Lymph Nodes :

LEVEL 1	LEVEL 2	LEVEL 3
BELOW AND LATERAL TO PECTORALIS MINOR	In between two pectorals (Interpectoral)	Above and medial to pectoralis minor
3 groups 1. Anterior 2. Lateral 3. Posterior	Central/Interpectoral/Rotter LN	Apical